


CASE REPORT

Electroconvulsive therapy in a patient with hypertrophic cardiomyopathy: A case report

Marco Kufner¹  | Caroline Nothdurfter¹ | Dagmar Steffling¹ | Andrea Baessler² | Lars S. Maier² | Yasmin Qamar²

¹Klinik und Poliklinik für Psychiatrie und Psychotherapie der Universität Regensburg am Bezirksklinikum Regensburg, Universitätsstr, Regensburg, Germany

²Klinik und Poliklinik für Innere Medizin II, Universitätsklinikum Regensburg, Regensburg, Germany

Correspondence

Marco Kufner, Klinik und Poliklinik für Psychiatrie und Psychotherapie, der Universität Regensburg am Bezirksklinikum Regensburg, Universitätsstr, 84, Regensburg 93053, Germany.
Email: marco.kufner@ukr.de

Abstract

The use of electroconvulsive therapy (ECT) in patients with underlying cardiac disease like hypertrophic cardiomyopathy (HCM) remains without satisfactory clinical guidelines. We provide a case report of successful application of ECT in a 43-year-old patient with bipolar disorder and comorbid HCM, including detailed diagnostic information and outlining key clinical considerations.

KEYWORDS

bipolar disorder, case report, electroconvulsive therapy, hypertrophic cardiomyopathy, major depressive disorder

1 | INTRODUCTION

Mental disorders often co-occur with cardiologic comorbidities.¹ Thus, it is important for mental health practitioners to have access to guidelines for patients underlying cardiologic comorbidities, as those lead to further morbidity. For treatment-resistant depressive episodes, electroconvulsive therapy (ECT) is among the most effective recommended treatment options. A comorbidity with hypertrophic cardiomyopathy (HCM) is considered a high-risk constellation for an ECT treatment and the decision pro or contra ECT remains an individual case decision without clear clinical guidelines. Also, case reports of ECT in HCM are rare² within the literature on ECT treatment of depression or bipolar disorder with cardiologic comorbidities.

In current clinical practice, ECT is used for the treatment of therapy-resistant depression, depression of psychotic subtype as well as in therapy-resistant depressive episodes of bipolar disorder. It is typically applied for 6 to 12 sessions with a frequency of 2 to 3 times per week in presence of a psychiatrist and an anesthesiologist. However, doubts about the evidence for ECT have been raised regarding critical side effects like neurocognitive deficits. This has triggered a critical review of ECT use.³ The cardiovascular side effects of ECT reflect those of a generalized seizure starting with a parasympathetic predominance during the tonic phase and a subsequent sympathetic reaction during the clonic phase of the seizure.² Cardiac arrhythmias are also considerable side effects of seizures: Temporal seizures are prone to show ictal asystoles which might be caused by a central stimulation of

This is an open access article under the terms of the [Creative Commons Attribution-NonCommercial-NoDerivs](https://creativecommons.org/licenses/by-nc-nd/4.0/) License, which permits use and distribution in any medium, provided the original work is properly cited, the use is non-commercial and no modifications or adaptations are made.

© 2022 The Authors. *Clinical Case Reports* published by John Wiley & Sons Ltd.

the autonomic nervous system as well as a vasovagal reflex.⁴ In up to 80% of all seizures, sinustachycardia can be observed as the most common cardiac consequence and is evaluated as appropriate vegetative reaction to ECT indicating a satisfactory seizure quality. Especially when obstruction is present, the tachycardic episode following an ECT session bears substantial risk of decreased left ventricular output.

Hypertrophic cardiomyopathy has first been described in 1869 by Henri Liouville, and later in the 1950s in context with sudden cardiac death.⁵ It is the most common genetic cardiomyopathy and is known to be an important cause of cardiovascular morbidity and mortality across all ages. Its prevalence in the general population has been previously estimated to be about 1:500, and recent investigations showed that globally 20 million people are affected by this autosomal dominantly inherited disorder. Meanwhile, a variety of mutations associated with modifications of cardiac myocytes have been described. Clinical diagnosis is usually made by echocardiography or cardiac magnetic resonance imaging (MRI), whereas for genetic testing a great diversity of mutations is known. The areas of myocardial fibrosis accompanying the disease can serve as sources for arrhythmia.⁶ Therefore, a careful cardiologic examination is required for an ECT treatment.

2 | CASE EXAMINATION

The 43-year-old caucasian male industrial worker with a history of a bipolar II disorder was admitted with a severe amotivational/anhedone depressive episode with psychotic symptoms, suicidal tendencies, and mood-congruent delusions of guilt. Up to this time, he had suffered several moderate to severe depressive episodes and a few hypomanic episodes which had been treated mainly ambulatory with a plethora of antidepressant medication including neuroleptics and mood stabilizers. He also received repetitive transcranial magnetic stimulation over several months without any effect. In the current admission, he showed a persistent depressed mood, loss of interest in activities he formerly enjoyed, appetite loss, loss of hope, social withdrawal, and concentration deficits. The patient reported that 16 years ago during a severe depressive episode, ECT was applied with a positive therapeutic effect lasting several months. Comorbidities were an essential stage 1 hypertension (ESC / ESH guidelines) and chronic kidney disease with a mildly decreased glomerular filtration rate. No family history of cardiac or psychiatric pathologies were reported by the patient. At the admission time, he had

been treated with lamotrigine, a tricyclic antidepressant (imipramine) and lithium, of which the latter was discontinued due to the renal impairment.

3 | DIFFERENTIAL DIAGNOSIS, INVESTIGATIONS, AND TREATMENT

At the time of hospital admission, the patient showed an athletic constitution without further abnormalities in the physical and neurologic examination. Upon admission, he scored 31 on the Beck depression inventory (BDI) indicating a severe depressive episode. A cranial MRI scan showed no intracranial pathologies. Neuropsychological tests showed cognitive, attentional, and memory functions within a lower normal to mildly impaired range.

Shortly before the psychiatry admission, he was diagnosed with hypertrophic cardiomyopathy, after repolarization abnormalities had been recognized in a routine electrocardiogram (ECG—see [Figure 1](#)). Subsequently, hypertrophic cardiomyopathy had been diagnosed using echocardiography and MRI, indicating concentric left ventricular hypertrophy particularly in the apex and medial third of the left ventricle (see [Figures 2 and 3](#)). Myocardial fibrosis has initially been considered by echocardiography but could not be detected by MRI. An obstruction of the LVOT was not evident, and no ventricular arrhythmias had been reported so far. However, on further inquiry, the patient reported two unexplained syncope.

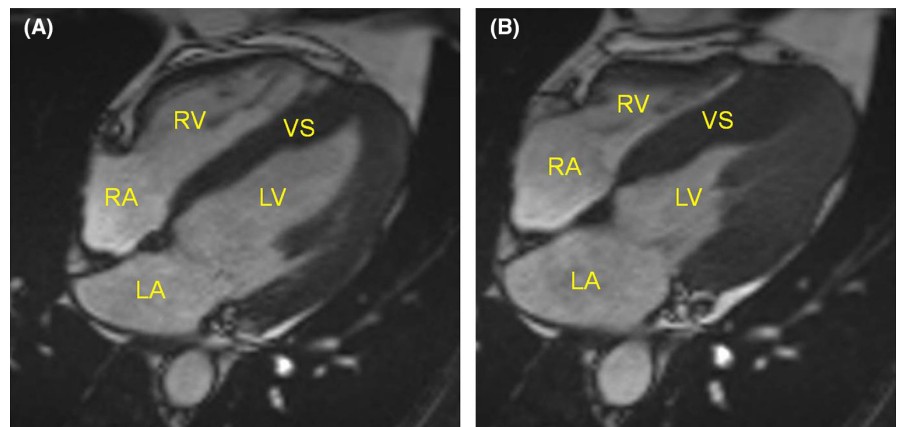
Prior to treatment, coronary artery disease had been excluded by coronary angiography. We calculated an HCM risk-SCD score of 3.5% according to 2014 ESC guidelines, considering age, maximum LV wall thickness (16 mm), left atrial diameter (43 mm), maximum LV outflow gradient (6 mmHg), and unexplained syncope in the patient history.⁷ In patients with a 5-year risk of SCD <4%, an ICD is generally not indicated. In our case, we therefore decided against the implantation of an ICD for primary prevention. Late gadolinium enhancement (LGE) by cardiac MRI is also a known predictor of adverse cardiovascular outcome, such as malignant ventricular arrhythmias and fibrosis itself and should thus be included into the decision pro or contra ICD. Taken into account that such additional risk factors are not sufficiently displayed within the SCD risk score, it has been shown that the present risk score is lacking sensitivity and leaves certain patient groups unprotected.⁶

In our case, the decision for a medicinal treatment with bisoprolol had been made; further cardiologic drug treatment was not necessary. Due to the cardiologic risk constellation, the psychiatric medication with lamotrigine and

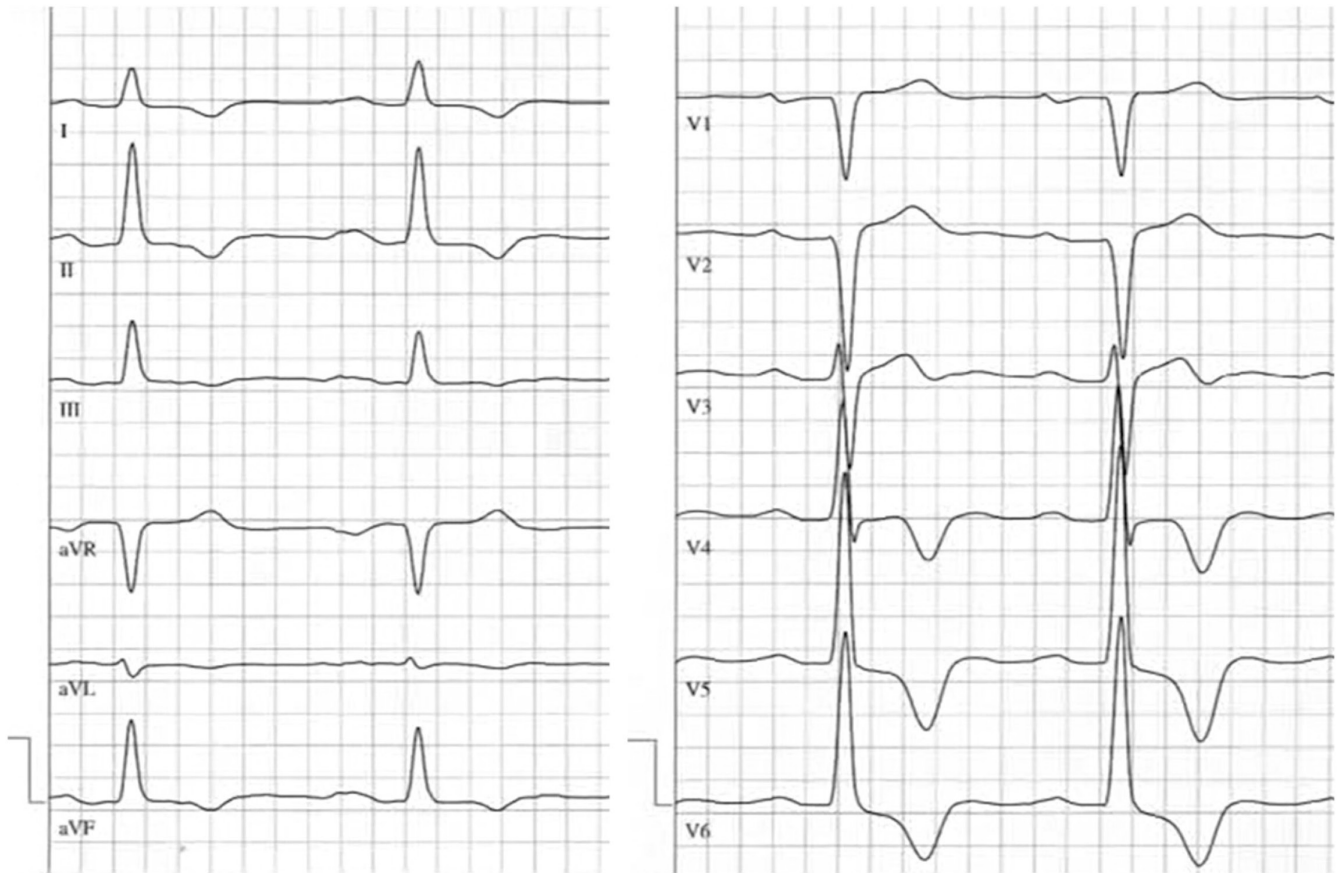

FIGURE 1 Electrocardiography. Negative T-waves and a positive Sokolov–Lyon Score indicate left ventricular hypertrophy

FIGURE 2 Magnetic resonance imaging, SSFP sequences. (A) diastole; (B) systole. RA denotes right atrium, RV right ventricle, LA left atrium, LV left ventricle and VS ventricular septum, indicating a concentric hypertrophic cardiomyopathy mostly stressed in the apex and medial third of the left ventricle



imipramine at admission time was discontinued and ECT treatment was started under a co-medication of sertraline (125 mg/d) and olanzapine (dose increase up to 30 mg/d). Twenty trains of ECT were performed without complications resulting in a substantial but short-lasting improvement in patients' symptomatology (see Figure 4). Right unilateral (d'Elia position) stimuli of 302.4–352.8 mC strength, pulse width 0.5 ms, and a frequency of 50 Hz were applied via a Thymatron System IV ECT device. Stimulation strength

was determined using an age-adapted formula. General anesthesia during ECT was performed using ketamine and propofol. For muscle relaxation, mivacuronium was used. All sessions were performed under continuous readiness for defibrillation and reanimation.

ECG monitoring of an ECT session showed a short sinus arrest followed by a sinustachycardia (see Figure 5). Repolarization after the ECT stimulus application showed no difference to pre-stimulation ECG. Holter ECGs showed

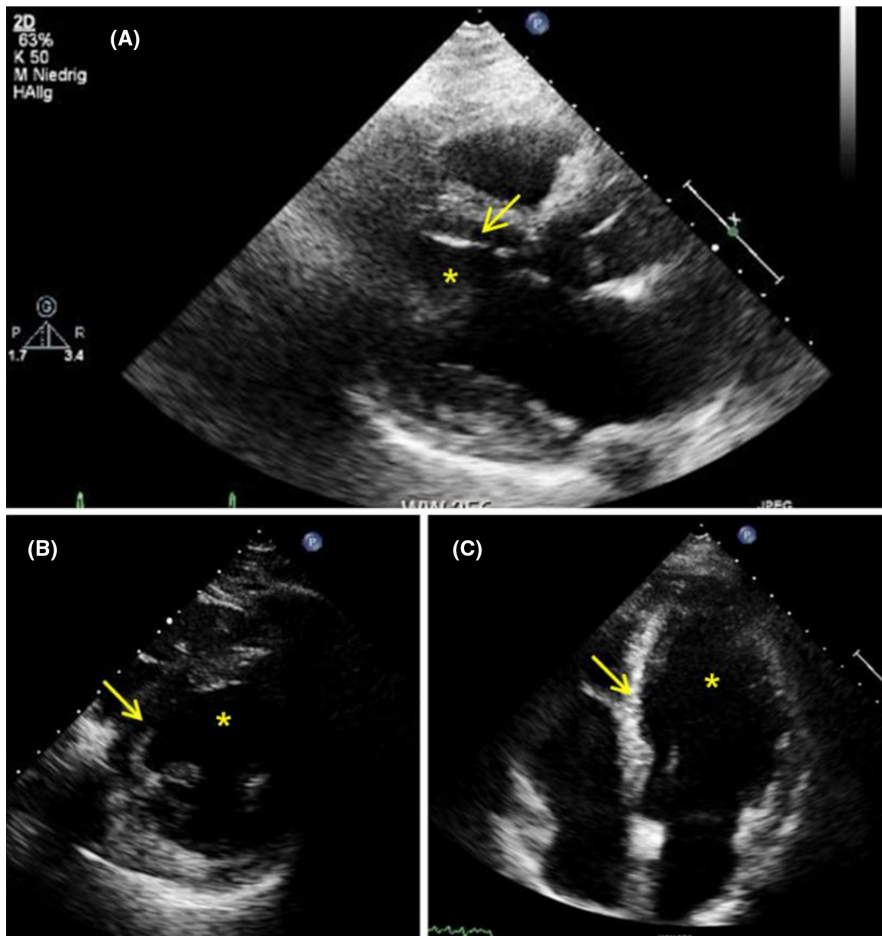


FIGURE 3 Echocardiography examples. (A) parasternal long axis; (B) parasternal short axis; (C) apical view. Left ventricle (asterisk), ventricular septum (arrow) with left ventricular hypertrophy

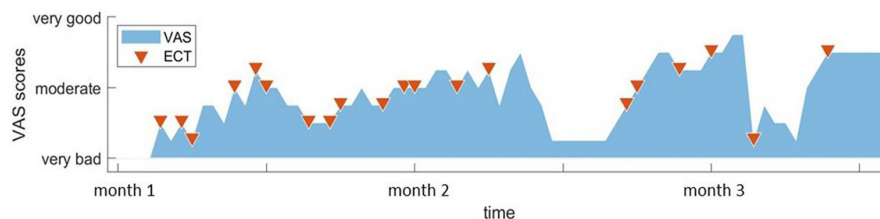


FIGURE 4 Clinical time course during ECT. The area resembles the subjective ratings of the patient on a visual analogue scale (VAS) between “very bad” to “very good.” Red triangles indicate the ECT dates. A rise in scores during ECT therapy with an immediate setback after ECT discontinuation (after 2.5 months) is observable. At the end of the observation time (end of blue area), subjective VAS ratings reflected a good clinical state after a second setback at time of hospital discharge (after 3 months).

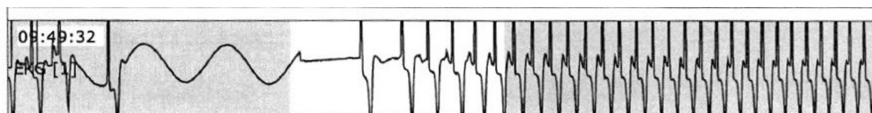


FIGURE 5 ECG monitoring during ECT. A sinus arrest of 8 s followed by a sinustachycardia of approximately 130 beats per minute is observable

a stable sinus rhythm with only occasional ventricular and supraventricular extrasystoles and irregular repolarization mostly comprehensible in the context of hypertrophy. No ventricular arrhythmias were observed. After the first train of ECT (14 sessions), the patient showed a substantial improvement in subjective mood and motivation as in clinical appearance with no further delusional symptoms (BDI: 11).

4 | OUTCOME AND FOLLOW-UP

After a 2-week period, he suffered a relapse of depressive symptoms and ECT was continued for another 6 sessions. Thereby, a significant improvement was reached where the patient could resume work receiving weekly ambulatory ECT sessions over 1 month. After 1 month of

maintenance ECT, the patient ended the treatment remaining stable under continued medication and outpatient psychotherapy.

Follow-up cardiac diagnostics showed a stable situation regarding the hypertrophic cardiomyopathy, still at an HCM-SCD-risk-score of 3.5%. No signs of progress of hypertrophy or obstruction could be found. Therefore, no modification of treatment had been made, and a cardiologic re-evaluation is planned 12 months later.

5 | DISCUSSION

We report the case of an ECT treatment without severe side effects in a bipolar patient with hypertrophic cardiomyopathy (HCM) and indicators of an intrinsic cardiac risk. Patients with HCM especially in advanced stages are prone to develop malign ventricular arrhythmias in the context of myocytal electric instability.

However, a patient should not be deprived of a potent therapy, such as ECT, due to unjustified concerns regarding adverse effects. Current findings suggest that risk of sudden cardiac death due to hypertrophic cardiomyopathy is low (less than 1% per year), as long as treatment is performed in accordance with current guidelines.⁶

This report adds further support to address the existing uncertainty and controversy of ECT in patients with significant cardiac comorbidities. As the presented case of HCM shows only mild structural cardiac abnormalities, we decided to perform ECT considering the formerly reported successful application in patient history, the patient's request and exhausted psychotherapeutic and pharmacological treatment options as well as the deteriorating clinical situation. The use of ECT had short-lasting positive effects on the psychiatric situation and allowed a transition to an outpatient care, and the patient was able to resume his employment and daily life activities.

The sinus arrest observed in the ECG during ECT is also commonly observable in generalized seizures, caused by an initially strong vagal stimulus followed by a sympathetic response. In other disease patterns, asymptomatic electrocardiographic pauses over few seconds can be frequently observed; furthermore, intermittent pauses of several seconds described as self-limiting ictal asystoles have been reported in context of seizures.⁴ As a result, we resolved to continue ECT treatment in the presented case. In obstructive hypertrophic cardiomyopathy, it is mentionable that the cardiovascular circumstances of a generalized seizure during ECT including hypertension and therefore increasing intraventricular pressure as well as diminished ventricular output may

potentially result in severe acute heart failure. In this context, Robinson et al.⁸ have shown that even in HCM with a mildly increased resting LVOT gradient no further increase of obstruction had been caused by ECT under pretreatment with beta-blocking medication (labetalol and esmolol). This report now additionally shows that ECT therapy in HCM may be feasible without complications under strict safety conditions: low HCM risk-SCD score with absence of late gadolinium enhancement and LVOT obstruction, lack of arrhythmia in holter ECG as well as bedside defibrillation therapy during the ECT sessions. Considering the latest discussion on ECT safety, experiences as the presented case seem valuable to drive further research.⁹

AUTHOR CONTRIBUTIONS

Kufner, Marco: Main Investigator psychiatric part—Patient admission and consent, diagnostic and clinical scoring, literature search, and manuscript preparation. Nothdurfter, Caroline: Psychiatric part—Diagnostic supervision and manuscript revision, ECT informed consent and conduction. Steffling, Dagmar: Anesthesiology: Pre-Treatment and narcosis conduction of ECT, intellectual input and revision of safety considerations, manuscript review. Baessler, Andrea: Cardiology part—Diagnostic supervision, therapeutic decision-making, and manuscript revision. Maier, Lars S.: Cardiology part—Diagnostic supervision and manuscript revision. Qamar, Yasmin: Main Investigator cardiology part—Cardiologic evaluation, diagnostics and clinical scoring, and manuscript preparation.

ACKNOWLEDGMENTS

We would like to thank Patrycja Ganslmeier for her support in the discussion of cardiologic findings and theoretical input during manuscript creation. Open Access funding enabled and organized by Projekt DEAL. WOA Institution: UNIVERSITAET REGENSBURG Consortia Name : Projekt DEAL

FUNDING INFORMATION

None.

DATA AVAILABILITY STATEMENT

Data available on request due to privacy/ethical restrictions.

CONSENT

The author has obtained written informed consent from the patient for this publication.

ORCID

Marco Kufner  <https://orcid.org/0000-0002-2177-3884>

REFERENCES

1. Igoumenou A, Alevizopoulos G, Anastasakis A, Stavrakaki E, Toutouzas P, Stefanadis C. Depression in patients with hypertrophic cardiomyopathy: is there any relation with the risk factors for sudden death? *Heart Asia*. 2012;4(1):44-48. doi:10.1136/heartasia-2012-010099
2. Adabag AS, Kim HG, al Aloul B. Arrhythmias associated with electroconvulsive therapy in hypertrophic cardiomyopathy. *Pacing Clin Electrophysiol*. 2008;31(2):253-255. doi:10.1111/j.1540-8159.2007.00979.x
3. Read J, Kirsch I, Mcgrath L. Electroconvulsive therapy for depression: a review of the quality of ECT versus sham ECT trials and meta-analyses. *Ethical Hum Psychol Psychiatry*. 2019;21(2):64-103.
4. Van Der Lende M, Surges R, Sander JW, Thijs RD. Cardiac arrhythmias during or after epileptic seizures. *J Neurol Neurosurg Psychiatry*. 2016;87(1):69-74. doi:10.1136/jnnp-2015-310559
5. Braunwald E. Hypertrophic cardiomyopathy: the first century 1869–1969. *Glob Cardiol Sci Pract*. 2012;2012(1):5. doi:10.5339/gcsp.2012.5
6. Maron MS, Rowin EJ, Wessler BS, et al. Enhanced American College of Cardiology/American Heart Association strategy for prevention of sudden cardiac death in high-risk patients with hypertrophic cardiomyopathy supplemental content. *JAMA Cardiol*. 2019;4(7):644-657. doi:10.1001/jamacardio.2019.1391
7. O'Mahony C, Jichi F, Pavlou M, et al. A novel clinical risk prediction model for sudden cardiac death in hypertrophic cardiomyopathy (HCM risk-SCD). *Eur Heart J*. 2014;35(30):2010-2020. doi:10.1093/eurheartj/eh439
8. Robinson AR, Holbert R, Modell JH, Gravenstein N. Continuous transthoracic echocardiography in a 93-year-old patient with hypertrophic cardiomyopathy during electroconvulsive therapy. *J ECT*. 2011;27(3):224-226. doi:10.1097/YCT.0b013e318223821b
9. Crisancho MA, Satterthwaite TD, O'Reardon JP. Cardiac complications of ECT: myocardial stunning syndrome and takotsubo cardiomyopathy after ECT different names for the same phenomenon. *J ECT*. 2010;26(2):146-147.

How to cite this article: Kufner M, Nothdurfter C, Steffling D, Baessler A, Maier LS, Qamar Y. Electroconvulsive therapy in a patient with hypertrophic cardiomyopathy: A case report. *Clin Case Rep*. 2022;10:e06286. doi: [10.1002/ccr3.6286](https://doi.org/10.1002/ccr3.6286)